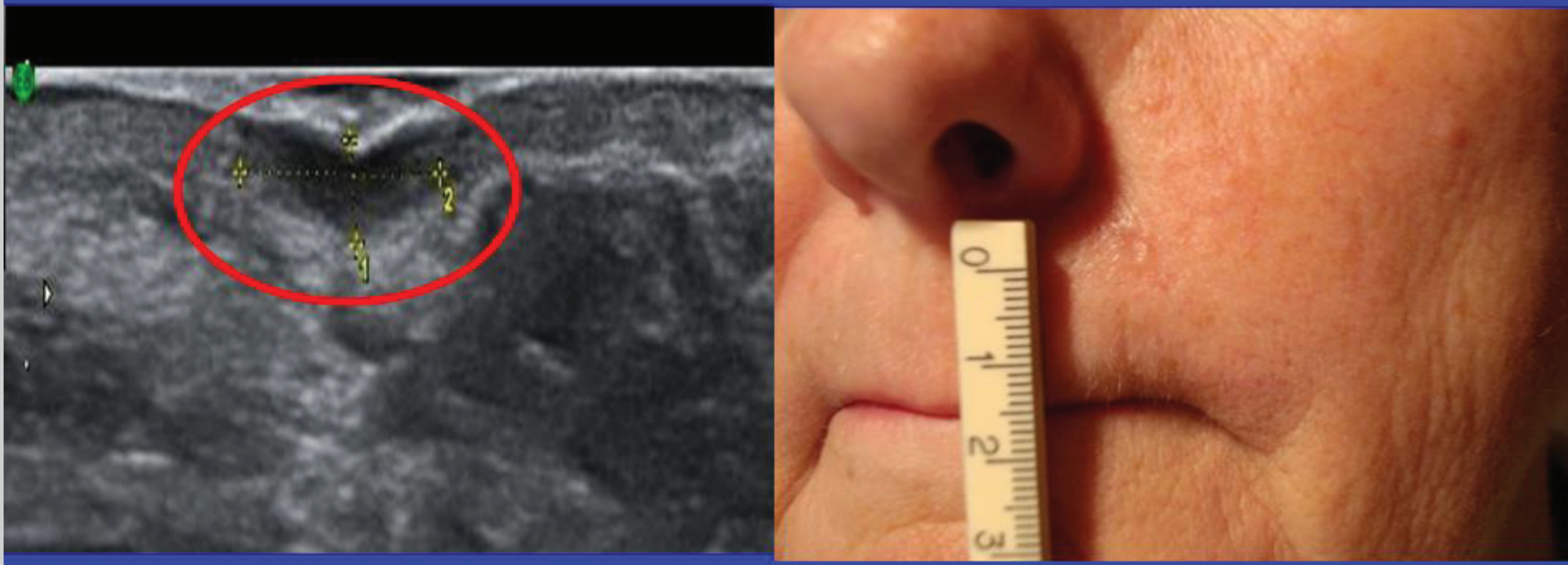


# 3D DOPPLER MAPPING OF CUTANEOUS LYMPHOMA

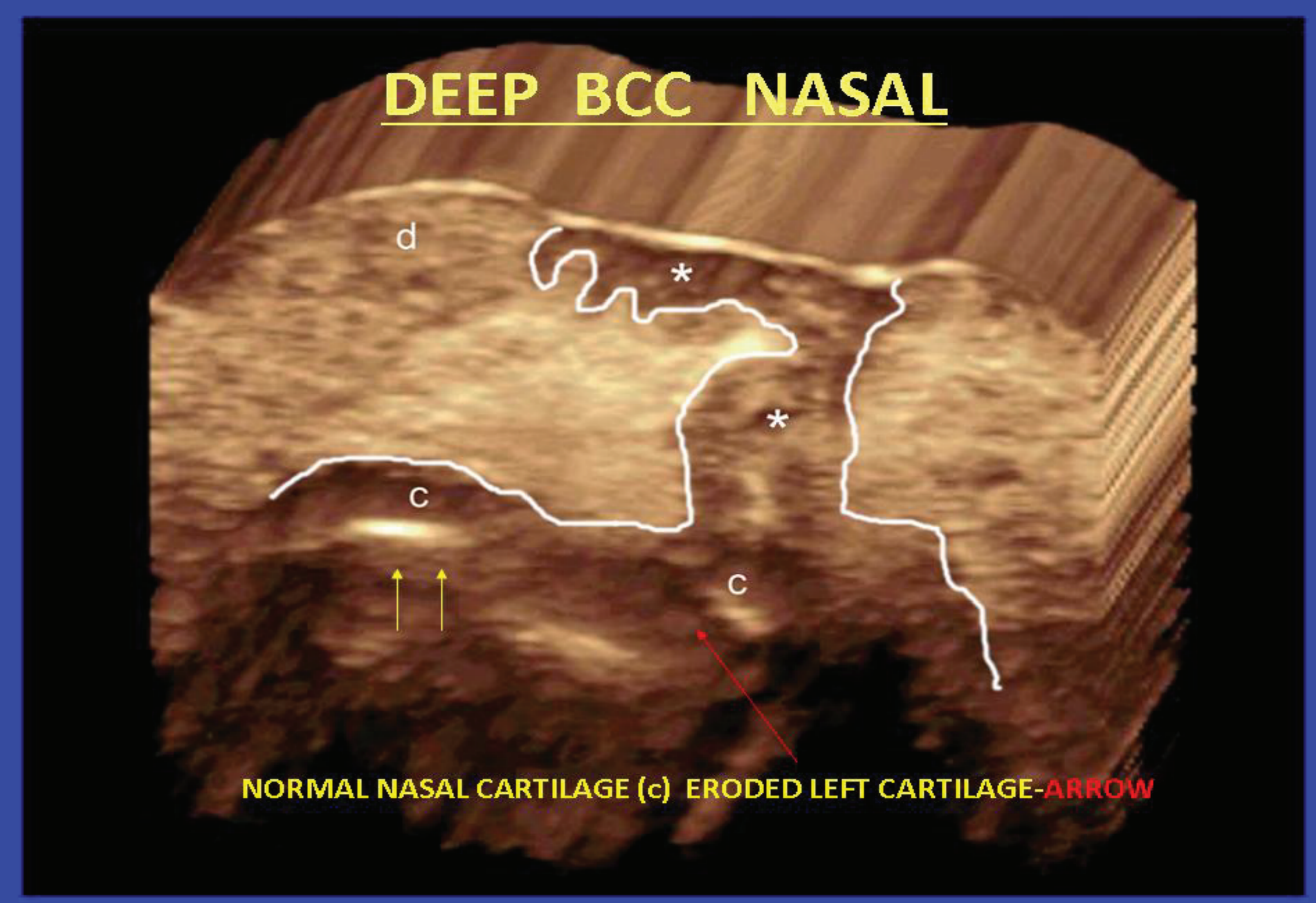
By: Robert L. Bard, MD, PC, DABR, FASLMS

## DEPTH OF TUMOR NOT VISIBLE TO EYE



BCC DEPTH = 1.5 MM AXIAL LENGTH = 6.0 MM

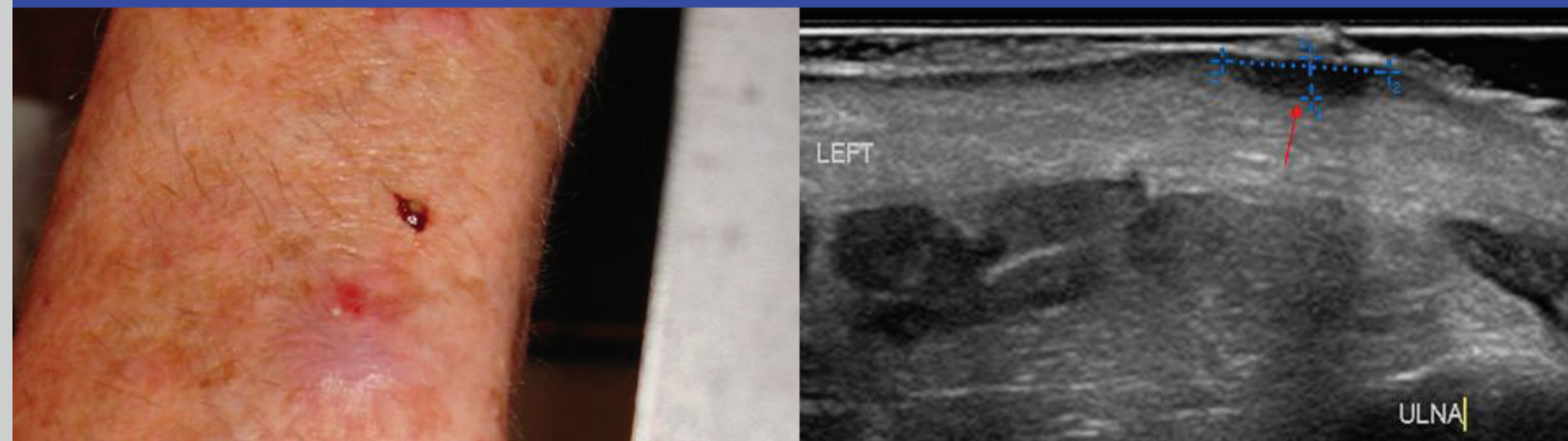
## DEEP BCC NASAL



NORMAL NASAL CARTILAGE (c) ERODED LEFT CARTILAGE-ARROW

## RECURRENT SCC

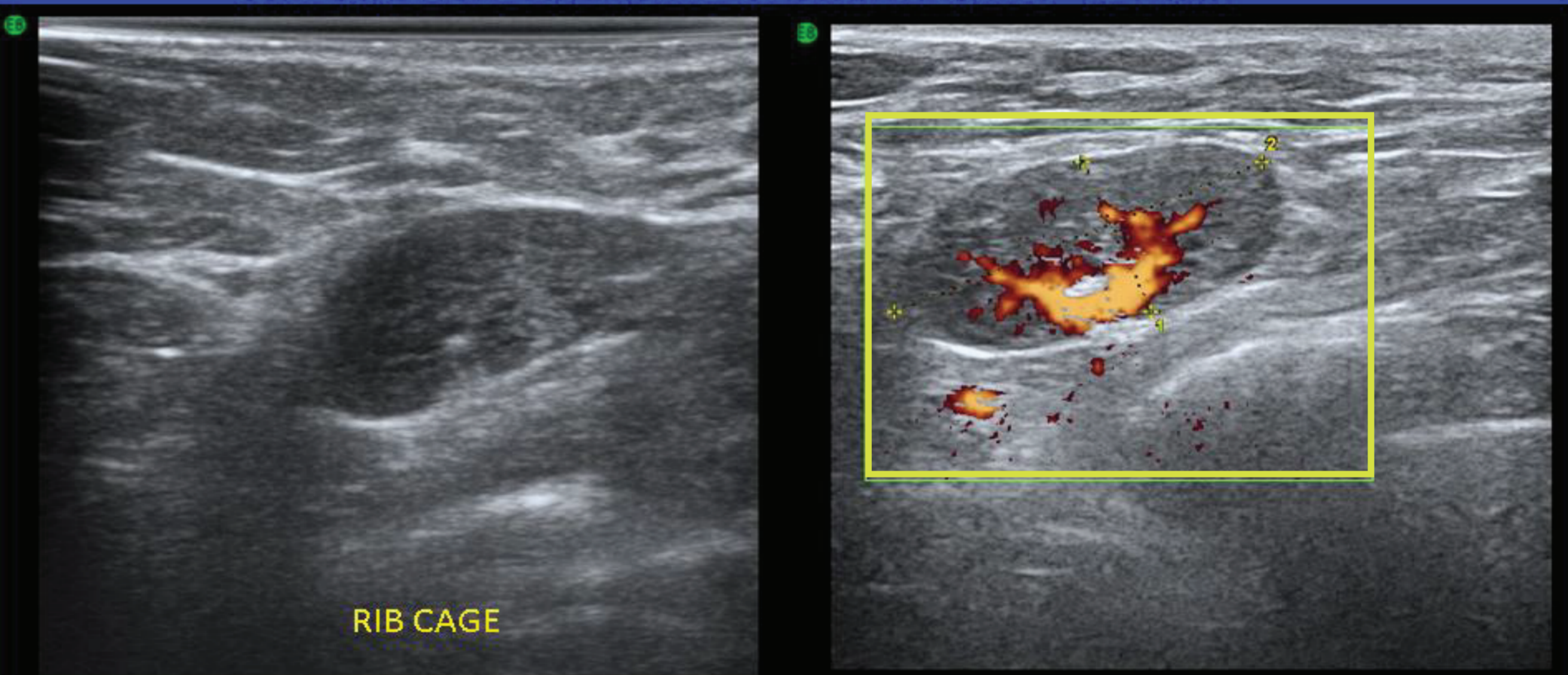
LESION DEPTH 900 MICRONS WIDTH 4.7 MILLIMETERS



NMSC WITH EPIDERMAL IRREGULARITY ADJACENT LT ULNAR WRIST

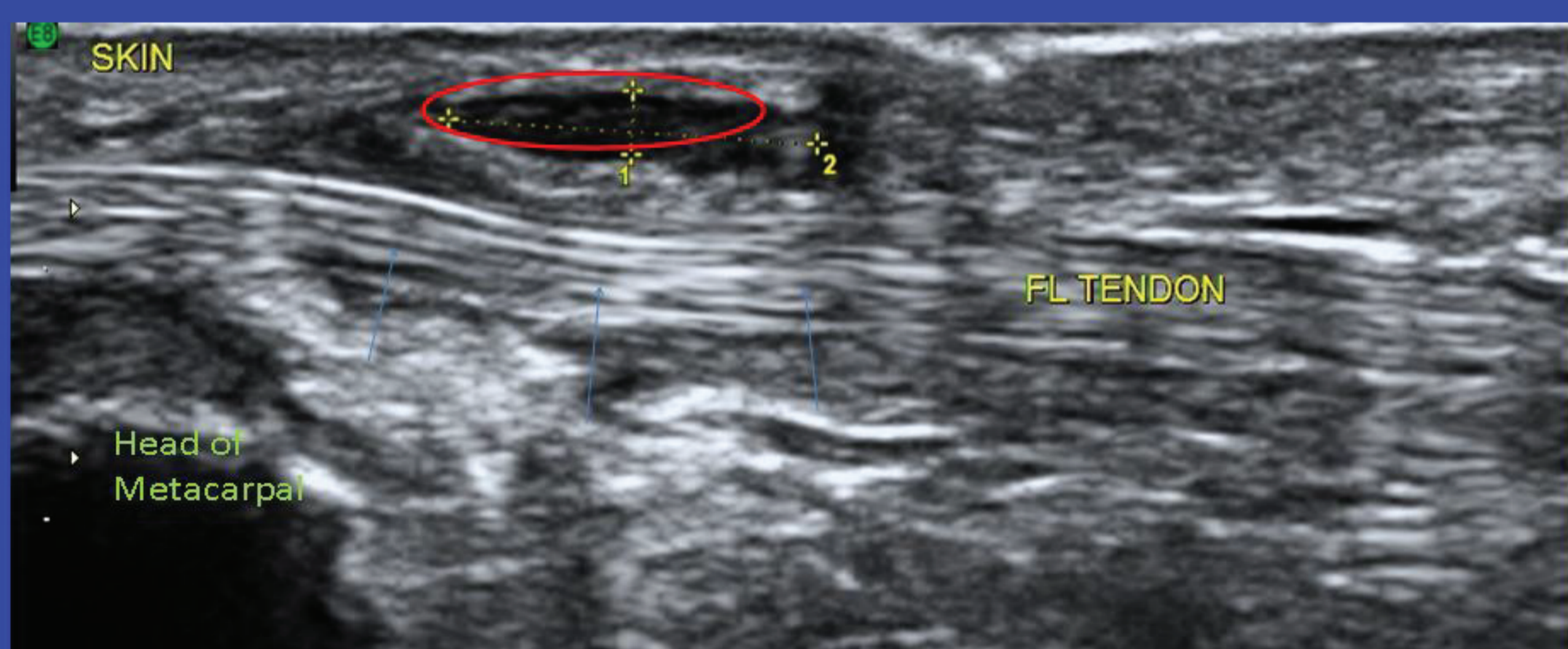
## INFLAMMATORY ADENOPATHY

AXILLARY NODE ENLARGING AFTER BEE STINGS TO ARM



RIB CAGE

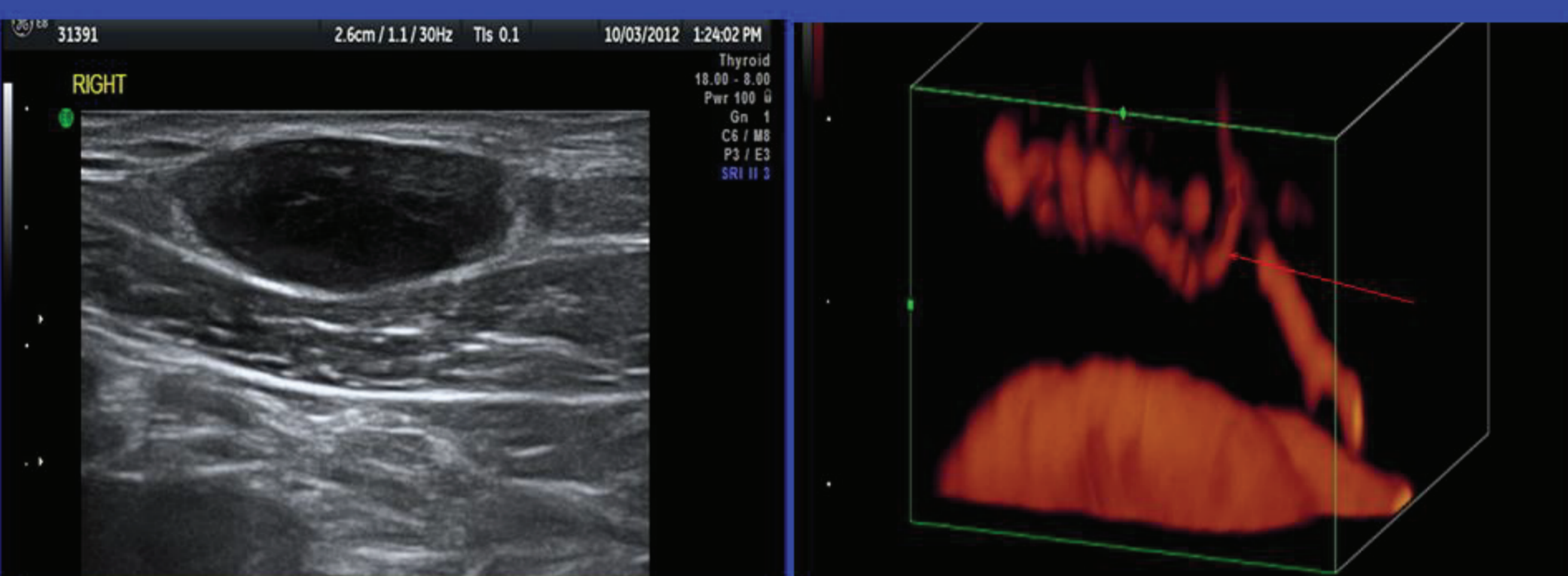
## SUBCUTANEOUS FIBROSIS



PALMAR SKIN - 1MM FLEXOR TENDON 2 MM PLAQUE 1X6 MM  
FNA-SPINDLE CELLS CONSISTENT WITH REACTIVE PROCESS  
NOTE DORSAL DEVIATION OF TENDON FROM FOCAL MASS EFFECT

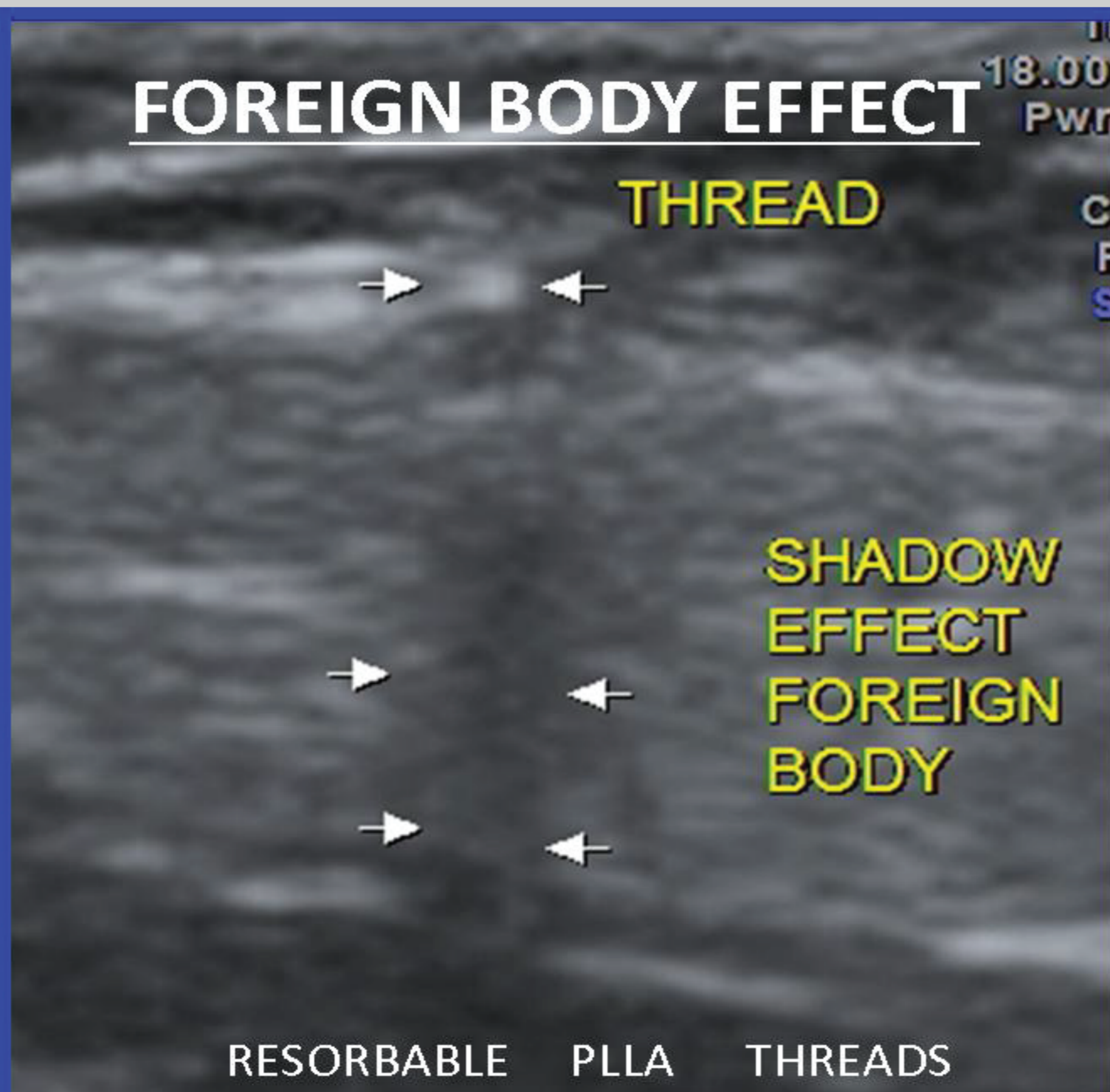
## VASCULAR METASTASIS

CLINICAL EXAM = LIPOMA SUBCLAVICULAR LOCATION  
PATHOLOGY=FOLLICULAR LYMPHOMA "FLORID TYPE"



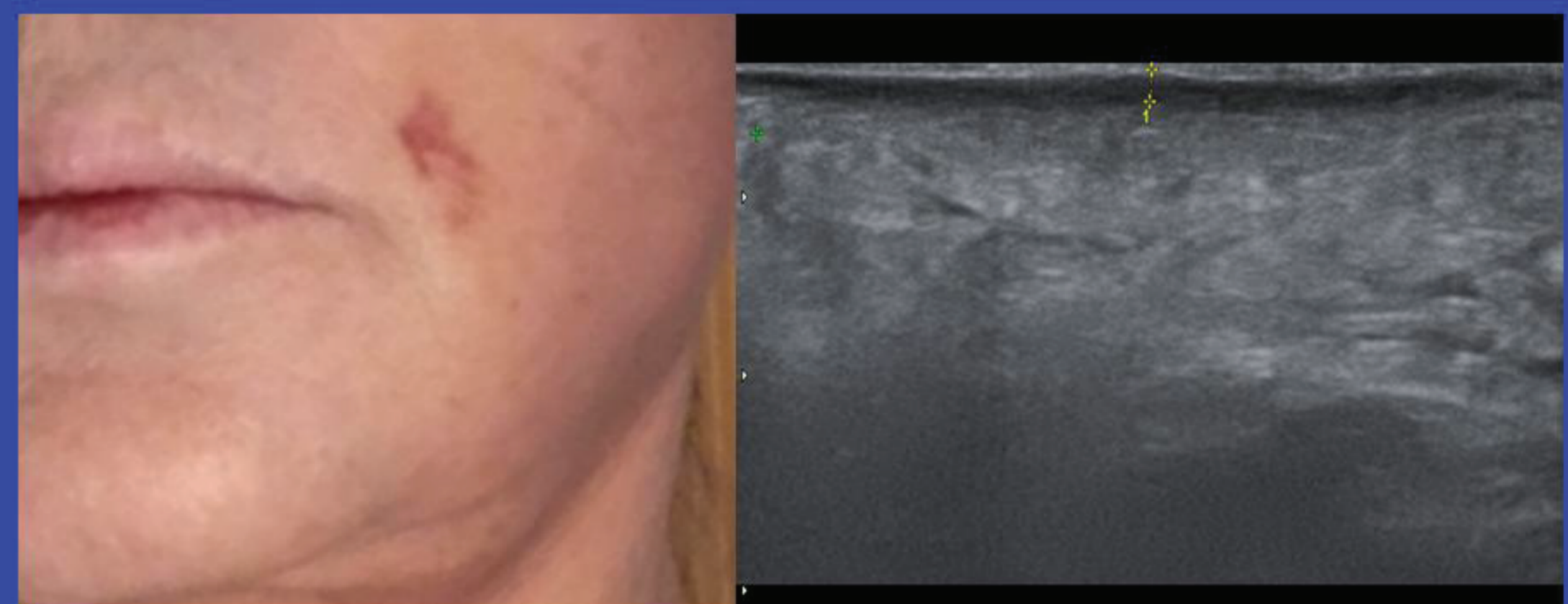
NOTE VASCULAR CONNECTING VESSEL FROM SUBCLAVIAN ARTERY

## FOREIGN BODY EFFECT



RESORBABLE PLLA THREADS

## INFLAMMED EPIDERMIS staph infection after thread insertion



NOTE RUBOR ASSOCIATED WITH  
1.1MM EPIDERMAL ENLARGEMENT